CellPress
OPEN ACCESS

Trends in
Cancer

Review

Everybody needs good neighbours: the progressive DCIS microenvironment

Shayin V. Gibson,[1] Reza M. Roozitalab,[1] Michael D. Allen,[1] J. Louise Jones,[1] Edward P. Carter,[1,*] and Richard P. Grose[1,*]

Ductal carcinoma *in situ* (DCIS) is a pre-invasive form of breast cancer where neoplastic luminal cells are confined to the ductal tree. While as many as 70% of DCIS cases will remain indolent, most women are treated with surgery, often combined with endocrine and radiotherapies. Overtreatment is therefore a major issue, demanding new methods to stratify patients. Somewhat paradoxically, the neoplastic cells in DCIS are genetically comparable to those in invasive disease, suggesting the tumour microenvironment is the driving force for progression. Clinical and mechanistic studies highlight the complex DCIS microenvironment, with multiple cell types competing to regulate progression. Here, we examine recent studies detailing distinct aspects of the DCIS microenvironment and discuss how these may inform more effective care.

Highlights

Identifying predictors of recurrence and invasive progression of ductal carcinoma *in situ* (DCIS) is a major clinical challenge.

Changes to the local microenvironment, rather than the neoplastic cells, are major contributors to progression.

The transition of DCIS to invasive ductal carcinoma (IDC) requires cumulative changes to the stroma to promote a tumour-permissive niche that facilitates local invasion.

Combining prognostic signatures from the DCIS microenvironment will be key for effective stratification of DCIS patients.

Clinical challenges of DCIS

Since the introduction of mammographic screening, the reported incidence of DCIS has increased, with over 8 000 women diagnosed each year in the UK[i]. In DCIS, neoplastic epithelial cells proliferate and fill the lumen of the breast duct, while remaining confined within the duct by an intact myoepithelial-basement membrane barrier (Figure 1). During the transition of DCIS to invasive ductal carcinoma (IDC), tumour cells are able to penetrate into the surrounding tissue, with concomitant loss of both the basement membrane (BM) and surrounding myoepithelial cells (Figure 1).

Although DCIS is a precursor lesion, studies suggest that between 50% and 70% of diagnosed DCIS cases will not progress to invasive disease [1–5]. However, with no current biomarkers available to predict disease progression, the standard treatment for the majority of DCIS patients consists of wide local excision with radiotherapy if the DCIS is limited, or a mastectomy if it is extensive. Thus, there has been growing concern regarding the overdiagnosis and overtreatment of many women [3,6–9], highlighting the clinical need to develop stratification methods for low-risk DCIS patients. Currently, histopathological diagnostic features, such as architectural morphology and nuclear grade, are used to classify DCIS into low, medium, or high grade. While some studies suggest that high-grade DCIS has a shorter time to progression [10,11], this association remains inconclusive [12,13]. As with invasive breast cancer, molecular classification can also guide DCIS management post-surgery, with adjuvant endocrine therapy offered for oestrogen receptor-positive DCIS patients. Approximately 40% of DCIS presents as human epidermal growth factor receptor (HER2) positive, and while HER2 overexpression is associated with increased risk of *in situ* recurrence, risk of invasive recurrence is not significantly affected [14,15], highlighting that molecular classification cannot be used to predict progression to the invasive stage. Currently, there is no consensus to treat HER2-positive DCIS patients with anti-HER2 therapy [16].

Identifying prognostic markers has proven difficult, with current guidelines recommending surgical excision of DCIS following detection, making the natural course of DCIS progression difficult to

[1]Centre for Tumour Biology, Barts Cancer Institute, Queen Mary University of London, London EC1M 6BQ, UK

*Correspondence:
e.carter@qmul.ac.uk (E.P. Carter) and r.p.grose@qmul.ac.uk (R.P. Grose).

 https://doi.org/10.1016/j.trecan.2023.01.002
© 2023 The Authors. Published by Elsevier Inc. This is an open access article under the CC BY license (http://creativecommons.org/licenses/by/4.0/).

CellPress
OPEN ACCESS

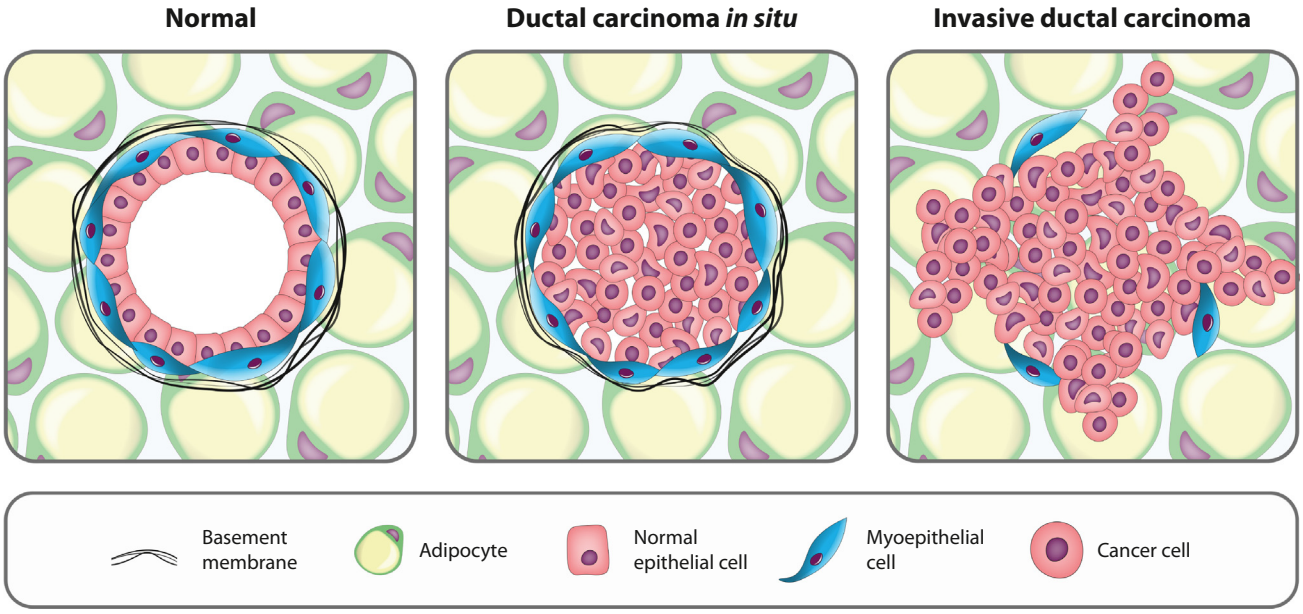

Figure 1. Canonical model of ductal carcinoma *in situ* (DCIS) progression. In the breast, ducts consisting of luminal and myoepithelial cells are encapsulated by a basement membrane and surrounding adipocytes. In DCIS, neoplastic cells proliferate to fill the lumen but are confined to the ductal space by an intact myoepithelial-basement membrane barrier. From DCIS, the disease can advance to invasive ductal carcinoma (IDC), which is characterised by a breach in the basement membrane, loss of the myoepithelial layer, and invasion of cancer cells into the surrounding stroma.

understand. Consequently, opportunities to identify progressive markers in large, unbiased cohorts with paired molecular profiling and long-term clinical follow-up have been limited. While cohorts examining recurrence following treatment (either as DCIS or IDC) are more readily available, they yield limited power, given low recurrence rates and lengthy time frames prior to recurrent presentation of disease. Clinical trials of treatment de-escalation, such as COMET, LORETTA, LORIS and LORD, have also been established to compare standard treatment with active surveillance over 10 years in cohorts of approximately 3000 patients with primary DCIS. However, the outcomes of these studies remain to be seen [7,17–19].

With these challenges, previous efforts to identify predictive signatures have instead focused on comparing the tumour cells in DCIS with those of IDC [20–23]. Unfortunately, these studies have yielded limited information, reporting no significant differences in the transcriptomic signature of neoplastic cells throughout disease progression. Interestingly, cells from pure DCIS exhibit the most divergent molecular profile compared with their healthy counterparts [20,22], suggesting that transcriptional changes that confer the potential for invasive spread are already present during pre-invasive stages. With a lack of distinct genetic changes between DCIS and IDC, the question arises as to whether the most critical changes underpinning DCIS progression lie in the DCIS microenvironment. This hypothesis has been supported by recent analysis, highlighting that the transition of DCIS to IDC requires changes to the stroma, promoting a tumour-permissive niche that facilitates local invasion [23–27]. Despite this, assessment of microenvironmental features is yet to be adopted in determining clinical prognosis. In this review, we discuss cell-type specific microenvironmental contributions to DCIS, considering key mechanisms that underpin the transition of DCIS to IDC (Figure 2). We also highlight the prognostic relevance of these key findings in the development of markers to predict disease progression and recurrence (Table 1).

DCIS and the microenvironment

Myoepithelial cells

In the healthy breast duct, myoepithelial cells are positioned at the interface between luminal cells and the BM and act as a physical barrier against luminal cell invasion into the surrounding stroma (Figure 1). In addition to their contractile properties, which support the ejection of milk during lactation, myoepithelial cells contribute to the synthesis and organisation of the BM through secretion of laminin and collagen IV, helping to regulate the differentiation and polarity of luminal epithelial cells [28–33]. Their ability to induce cancer cell cycle arrest and halt invasion *in vitro*, potentially through expression of endogenous protease inhibitors [34], demonstrates their tumour-suppressive nature, which is emphasised by *ex vivo* DCIS studies that demonstrate the ability of myoepithelial cells to actively restrain and restrict the escape of neoplastic luminal cells [35]. As the loss of myoepithelium is a key pathological determinant in distinguishing between DCIS and IDC (Figure 1) [36], there is extensive interest in understanding how they are lost and what their role is in modulating disease progression [28,37]. However, the progressive loss in their differentiation markers prior to invasion [38] makes myoepithelial cells difficult to discern pathologically and renders them indistinguishable from surrounding fibroblasts.

Surprisingly, transcriptomic analysis of distinct cell types within breast tissue samples, utilising cell-specific surface markers, revealed that gene expression changes were already present across several stromal cell types at the DCIS stage. Strikingly, out of the cells of the tumour microenvironment, DCIS-associated myoepithelial cells showed the most significant transcriptomic change of any cell type, compared with their normal counterparts [39], although as CD10 expression was used to isolate myoepithelial cells from DCIS organoids, distinct myoepithelial subsets which lacked CD10 may have been excluded in this study [39]. Concomitant with this, spatial analysis of tissue from the Washington University Resource Archival Human Breast Tissue (RAHBT) cohort, consisting of matched primary DCIS lesions from women who later showed recurrent DCIS with invasive disease, revealed that myoepithelial integrity was key in predicting disease progression. Counterintuitively, this study has suggested that a thin, discontinuous myoepithelium was more likely in the DCIS lesions of nonprogressing patients, while lesions with more continuous myoepithelium were at higher risk of invasive recurrence [27]. As the retention of the myoepithelium was correlated with fewer infiltrating immune cells, one possibility is that the discontinuous myoepithelium present in nonprogressing patients may allow for immune cell entry and tumour cell killing during the early stages of disease, although data to support the prognostic relevance of infiltrating immune cells in DCIS remain contradictory [40–43]. An additional interpretation of this finding is that DCIS-associated myoepithelial cells may lose their naturally tumour-suppressive phenotype, pointing to their potential role as active drivers in the transition of DCIS to IDC. While this study raises a novel hypothesis, it is important to note that pan epithelial E-cadherin was used to identify myoepithelial cells, rather than myoepithelial-specific P-cadherin, in a limited number of patients with progression, highlighting a need for further validation with additional myoepithelial-specific markers in a larger cohort.

Nevertheless, functional *in vitro* assays support an altered role for the myoepithelium, with myoepithelial cells losing their ability to correctly polarise luminal cells in DCIS, through reduced secretion of BM proteins such as laminin I [44]. Tumour-promoting effects of the DCIS myoepithelium have also been displayed, with co-culture studies demonstrating myoepithelial cell-enhanced cancer cell proliferation and migration, through increased expression of the C-X-C motif chemokines ligands (CXCL) 12 and CXCL14 [39], and secretion of several matrix metalloproteinases (MMPs) [45–47]. Increased secretion of myoepithelial transforming growth factor beta (TGFβ) can also drive induction of epithelial-mesenchymal transition (EMT)-related genes, such as *FOXC2*, *SNAIL*, *ZEB1/2*, and *VIM1* in the MCF10DCIS cell line model [48]. Finally, xenograft studies have shown that co-injection of tumour-associated (Hs578Bst) or integrin β6-positive (β6-1089) myoepithelial cells, together with

CellPress
OPEN ACCESS

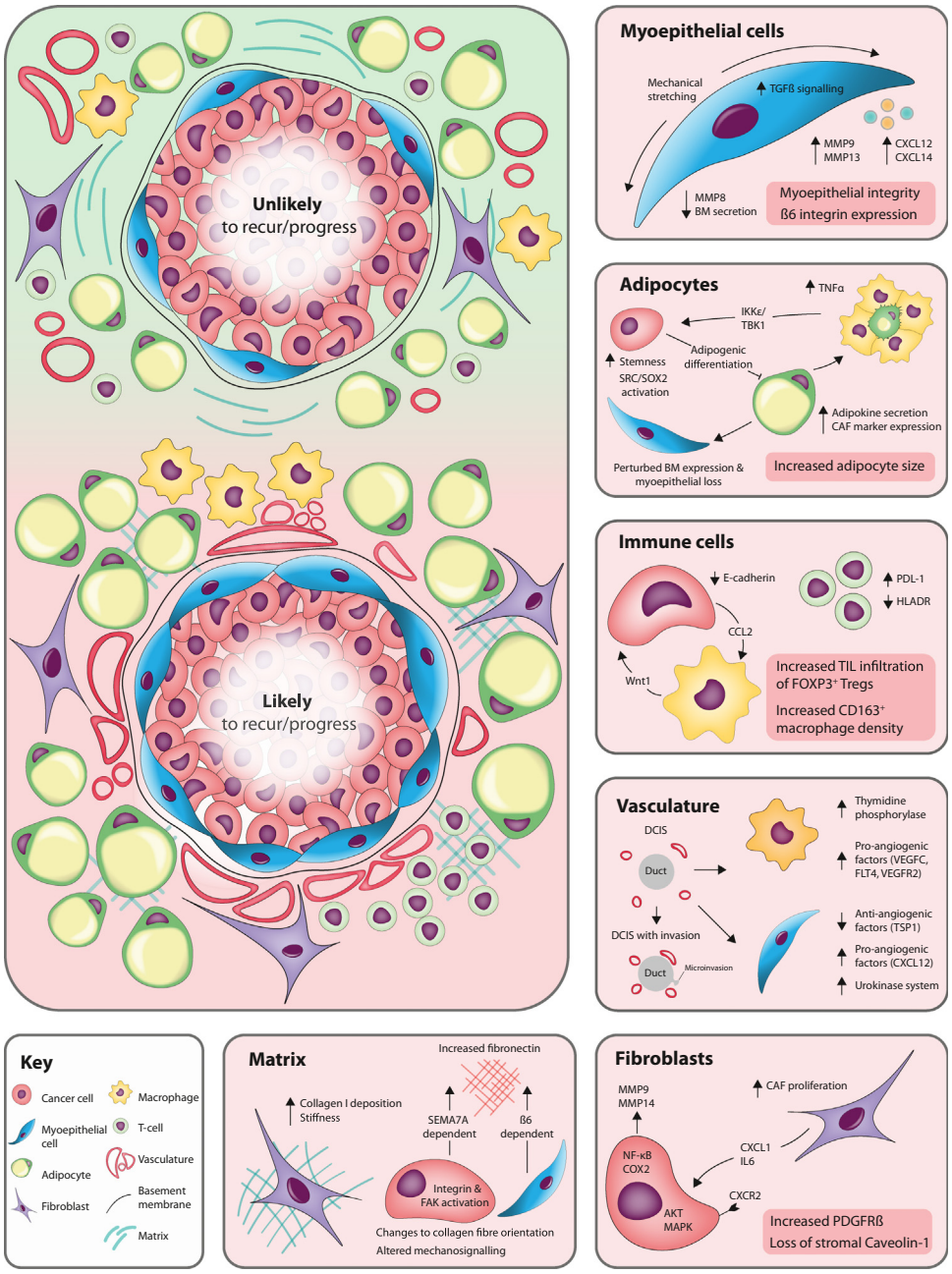

Figure 2. Role of the ductal carcinoma *in situ* (DCIS) microenvironment in facilitating DCIS progression. There are currently no biomarkers available to predict DCIS recurrence and progression in the clinic. Tumour-microenvironment crosstalk may facilitate DCIS recurrence and progression to invasive disease. This schematic highlights cell type-specific molecular mechanisms, which could act as potential prognostic markers of indolent DCIS (unlikely) or DCIS progression (likely). Mechanical stretching of the myoepithelium in DCIS drives upregulation of integrin β6, activation of TGFβ signalling, and downstream changes in expression of basement membrane (BM) proteins, proteases, and chemokines. Cancer cells can block differentiation of adipocytes, promoting increased adipokine secretion and expression of CAF markers in adipocytes, which may in turn promote stem-like characteristics of cancer cells through activation of SRC/SOX2 pathways. Adipocytes may also influence the fate of myoepithelial cells, altering expression of BM proteins. Inflammatory-mediated crosstalk in the breast adipose tissue

(Figure legend continued at the bottom of the next page.)

Table 1. Microenvironmental markers that show potential for predicting DCIS progression in the clinic

Marker	Microenvironmental compartment	Prognostic relevance	Refs
Established from patient cohorts with recurrence data			
β6 integrin expression	Myoepithelial	Increased myoepithelial β6 integrin expression is associated with high-risk DCIS	[46]
Myoepithelial integrity	Myoepithelial	Discontinuous myoepithelium may be present in the DCIS lesions of nonprogressing patients, while more continuous myoepithelium may be at higher risk of invasive recurrence	[27]
Adipocyte size	Adipocyte	Large breast adipocyte size associated significantly with subsequent ipsilateral invasive recurrence	[63]
Density of 'touching' TILs	Immune cells	Increased density of touching TILs (defined as TILs either touching the ductal BM or one lymphocyte cell thickness away) is predictive of a shorter recurrence-free interval in DCIS	[41]
$CD163^+$ macrophage density	Macrophages	Elevated presence of $CD163^+$ perivascular macrophages associated with increased likelihood of both DCIS and ipsilateral invasive recurrence	[72]
PDGFRβ expression	Fibroblasts	Increased expression of PDGFRβ associated with increased risk of recurrence	[98]
Caveolin-1	Fibroblasts	Loss of stromal Caveolin-1 may be associated with progression to IDC	[99]
Established from comparison between pure DCIS and DCIS with coexisting invasion or IDC			
Periductal vasculature	Vasculature	Periductal pattern may be associated with DCIS with coexisting invasion	[79]
Stiffness and collagen alignment	Matrix	Increased collagen I deposition and fibre orientation from parallel to perpendicular may be associated with invasion	[103–107]

cancer cells, can potentiate tumour growth in the mammary fat pad, further supporting their role in disease progression [46,48].

Despite increasing recognition that myoepithelial cells can adopt a tumour-promoting phenotype, the mechanism underpinning this switch is still unclear. One explanation could be attributed to the mechanical alterations exerted through myoepithelial stretching during DCIS progression [45],

promotes TNFα secretion by inflammatory macrophages, which may promote IKKε/TBK1-dependent malignant properties in DCIS cells. Establishment of an immunosuppressive stroma, characterised by increased $FOXP3^+$ TILs, and respective high and low expression of PDL-1 and HLADR, may promote DCIS progression. Cancer cell-derived CCL2-mediated recruitment of macrophages can drive increased Wnt-1 secretion and cancer cell loss of E-cadherin. Fibroblast-cancer cell mediated crosstalk drives cancer cell activation of NF-κB and COX-2, and upregulation of MMP9 and MMP14. Increased fibroblast secretion of CXCL1 and IL-6 can drive activation of AKT/MAPK pathways in DCIS cells. While a stromal vascular pattern is observed in pure DCIS, a periductal pattern can be observed in DCIS with an invasive component. Interestingly, increased pro-angiogenic factors are observed in pure DCIS, with an upregulation of VEGF-related proteins, suggesting a pre-existing angiogenic state prior to invasive progression. Compared with the healthy breast, myoepithelial cells display reduced expression of anti-angiogenic factor thrombospondin 1 (TSP1) and increased expression of pro-angiogenic factors, as well as upregulation of the urokinase system. Increased collagen I deposition and changes to fibre orientation and matrix stiffness can occur following activation of fibroblasts. Increased fibronectin deposition by DCIS cells, in a SEMA7A-dependent manner, and myoepithelial cells, in a β6-dependent manner, may also occur. The altered matrix drives changes in downstream mechanosignalling, particularly through integrin and FAK activation in DCIS cells. Features of the tumour microenvironment which may indicate the likelihood of DCIS progression and invasive recurrence are highlighted in associated boxes. Abbreviations: BM, basement membrane; CAF, cancer-associated fibroblasts; DCIS, ductal carcinoma *in situ*; PDGFRβ, platelet-derived growth factor receptor beta; TIL, tumour-infiltrating lymphocytes; TNFα, tumour necrosis factor α; VEGF, vascular endothelial growth factor.

where increased DCIS duct size is shown to correlate with β6 integrin upregulation and subsequent changes in the expression of BM degrading MMPs [45–47]. The prognostic relevance of myoepithelial β6 upregulation has been demonstrated in a cohort of DCIS patients with long-term follow-up [46], where myoepithelial αvβ6 integrin expression correlated with disease recurrence; β6 positive cases demonstrated a shorter time to recurrence compared with β6 integrin negative cases, at 2.3 years versus 11.4 years, respectively [46]. Thus, expression of the αvβ6 integrin in the myoepithelial compartment may help stratify high-risk DCIS patients likely to progress to IDC [46,49].

Adipocytes

Despite the established link between obesity and breast cancer [50,51], and the close proximity of adipocytes to the tumour margin, the role of the adipose microenvironment in facilitating disease progression has received little attention until recently. While adipocytes were historically considered as energy stores, evidence now points to their additional roles as active modulators of tumour growth, coining the term cancer-associated adipocytes (CAAs). Interactions between the tumour cells and the adipocyte microenvironment are reciprocal, with DCIS-cancer cells able to block adipogenic differentiation of pre-adipocytes and induce expression of fibroblast secreted protein-1 and α-smooth muscle actin, markers more commonly associated with cancer-associated fibroblasts (CAFs) [52]. CAAs in turn facilitate the proliferation and invasion of cancer cells in culture and enhance tumour growth in xenograft models [52]. Mechanistically, this is dependent on secretion of adipokines, such as leptin, chemokine (C-C motif) ligand 5 (CCL5), and hepatocyte growth factor (HGF), as well as proteases, including MMP11, which can support the invasion and dissemination of cancer cells into the stroma [53,54]. Adipocytes also have the capacity to promote a stem cell phenotype, observed across both DCIS and established breast cancer cell models [55,56], where exposure of cancer cells to adipokines drives tumour progression through activation of a SRC/SOX2-dependent pathway [55].

In addition to the tumour-adipose crosstalk, adipocytes are key mediators in determining the fate of other cells in the DCIS microenvironment. For instance, adipocytes have been demonstrated to disrupt the tumour-suppressive properties of myoepithelial cells. In co-culture experiments, incorporation of adipocytes alters myoepithelial expression of BM proteins laminin and collagen IV, as well as matrix-binding integrins [54]. Additionally, obese mouse models show an inverse correlation between body mass index and number of myoepithelial cells [57]. Adipose tissue is also a mediator of chronic inflammation, where elevated leptin can stimulate increased secretion of proinflammatory cytokines [tumour necrosis factor (TNF)α, interleukin (IL)-1β, cycloocygenase-2 (COX-2)] [58]. Sites of chronic inflammation also contain crown-like macrophage structures in the breast adipose tissue, and can be characterised by the encircling of necrotic adipocytes by TNFα-producing proinflammatory macrophages [59]. Interestingly, exposure of the nontumourigenic breast epithelial cell line MCF10A to medium conditioned by macrophages drives IKKε/TBK1 dependent acquisition of malignant properties, with pharmacological inhibition of this pathway delaying *in vivo* tumour formation in mouse models of obesity-associated breast cancer [60]. While presence of these crown-like structures in healthy breast is associated with increased breast cancer risk [59], their prognostic significance in DCIS is contentious [61,62]. Recent digital pathologic assessment of a DCIS cohort with long-term follow-up, consisting of 276 women treated surgically, revealed that adipocyte features could be used to predict recurrent invasive breast cancer [63]. Specifically, large breast adipocyte size associated significantly with subsequent ipsilateral invasive breast cancer (iIBC), with an odds ratio of 2.75 [63]. When large adipocyte size was combined with high DCIS COX2 expression, an additional marker identified in this same cohort [64], risk of subsequent iIBC was 12-fold higher [63]. While adipocyte size appears to be a promising marker in the clinical management of primary DCIS patients, it is important to note that patient data regarding margin status and lesion size were often missing and could present as confounding variables in this study [63].

Immune cells

In addition to the traditional hallmarks of cancer, such as dysregulated cell growth and apoptosis evasion, the ability to manipulate the immune system is a key characteristic of cancer cells [65]. Tumours have the ability to exert immunosuppressive signals as well as drive tumour-promoting inflammation, as a means to facilitate disease progression [66,67]. While anti-tumour responses can be extended through CD8+ cytotoxic T or CD20+ B lymphocytes, immunosuppressive responses are mediated through CD4+ FOXP3+ regulatory T cell activity. Cancer cells are able to hijack the immune system to activate immune checkpoint pathways, through a process termed 'immuno-editing', creating an immunosuppressive microenvironment [66].

In IDC, increased density of tumour-infiltrating lymphocytes (TILs) is associated with better treatment response and more favourable prognosis. This is supported by clinical trials, particularly in the context of triple-negative breast cancer (TNBC), that demonstrate the synergistic effects of TILs with chemotherapy treatment [68,69]. Despite its favourable prognosis in IDC, the significance of TILs in DCIS progression is less clear, with data displaying contradictory results [40–43]. While a lack of association between TILs and DCIS outcome has been reported in several studies [42,43], these studies utilised IDC recommended guidelines of TILs assessment, which may have not been appropriate in the context of DCIS. As not all stromal TILs are in contact with DCIS ducts, identifying TILs within the surrounding stroma of DCIS ducts can be challenging. Interestingly, when 'touching TILs,' which are defined as TILs either touching the ductal BM or one lymphocyte cell thickness away, were quantified instead, their density was predictive of a shorter recurrence-free interval in DCIS [41]. Thus, while increased TILs may be associated with increased immune-mediated tumour cell killing in IDC, increased immune cell infiltration in DCIS could be a sign of early inflammation, promoting remodelling of the BM and surrounding stroma to facilitate invasion [41]. Deconvolution of infiltrating immune cell subpopulations implicates higher infiltration of FOXP3+ T regulatory cells in DCIS associated with invasion, compared with pure DCIS [70], with shorter recurrence-free survival [40]. Concomitant with this, higher stromal expression of the programmed cell death ligand (PDL-1), as well as low human leukocyte antigen D-related receptor (HLADR), a marker for activated CD8+ T cells, are both implicated as prognostic markers of recurrence. Taken together, this highlights that even during the early stages of tumourigenesis, an enhanced immunosuppressive environment can be established to facilitate tumour cell invasion [40].

In addition to infiltrating lymphocytes, several myeloid cell types are associated with DCIS [71,72]. For example, HER2/NF-κB cancer cell signalling can promote CCL2-dependent recruitment of $CD206^{hi}$ macrophages, which in turn respond through increased Wnt-1 secretion to drive paracrine-mediated loss of cancer cell E-cadherin [73]. Indeed, DCIS samples with increased intra-epithelial macrophages show reduced E-cadherin expression [73], while depletion of macrophages in early-stage breast cancer mouse models can reduce early cancer cell dissemination [73]. The prognostic relevance of macrophages in DCIS can be highlighted by their increased abundance, defined by CD68 positivity, in high- versus low-grade DCIS [74]. Interestingly, DCIS with high macrophage density is associated with poor prognostic features, with the presence of high CD163, a marker of perivascular macrophages, indicative of both DCIS and ipsilateral invasive recurrence [72].

Vasculature

To facilitate tumour growth, the formation of new blood vessels is required to supply oxygen and nutrition to fast-proliferating cancer cells. In breast cancer, vascular endothelial growth factor (VEGF) expression and microvessel density represent useful prognostic markers for poor outcome [75,76]. In DCIS, two distinct vascular patterns have been described: the first being a diffuse stromal pattern, where an increase in vessels is observed in the surrounding stroma, and the second consisting of a periductal pattern, where vessels instead surround the DCIS-affected ducts

[75,77,78]. The periductal pattern has been shown to be associated with DCIS where a coexisting invasive component is present compared with pure DCIS, suggesting that the formation of periductal vessels may facilitate local invasion [79]. However, transcriptomic analysis of angiogenic markers offers a conflicting view, displaying increased expression of pro-angiogenic/lymphangiogenic factors (VEGF-C, FLT-4, and VEGFR2) in pure DCIS, compared to DCIS with coexisting invasion [80]. This was suggested to be due to biological differences in the vascular phenotype between the two states, with distinct pre-existing angiogenic patterns at the DCIS stage, prior to its evolution to invasive breast cancer [80]. The idea that DCIS and invasive disease can have different angiogenic phenotypes is supported by a study reporting positive correlation between stromal vascularity and expression of a pro-angiogenic regulator, thymidine phosphorylase, by perivascular inflammatory cells [81], observed only in DCIS patients and not patients with invasive disease.

Myoepithelial-regulated angiogenesis has also been implicated, with a benign myoepithelial tumour cell line series (HMS-1-6) inhibiting tumour-induced angiogenesis in xenograft models, potentially through their high expression of angiogenic inhibitors and low levels of pro-angiogenic factors [82]. As in the previous histological studies, conflicting results were reported upon gene expression and DNA methylation analysis in different breast cell populations, revealing a downregulation in the anti-angiogenic Thrombospondin-1 and upregulation of pro-angiogenic CXCL12 in myoepithelial cells from human DCIS compared with their normal counterparts [39,83]. Upregulation of the pro-angiogenic urokinase system has also been described in DCIS-associated myoepithelial cells [84], further contributing to the idea that myoepithelial cells may influence the angiogenic microenvironment, through an anti-angiogenic to pro-angiogenic switch. The phenotype is possibly dependent on the stage of progression, with angiogenic markers representing a tantalizing prospect for identifying patients at higher risk of DCIS progression.

Fibroblasts

Fibroblasts are located within the stroma of breast tissue, typically found near ductal structures. During the different stages of mammary gland development and pregnancy, they provide structural support through secretion of matrix proteins, which promote epithelial growth and differentiation. In addition to extracellular matrix proteins (ECM), fibroblasts also secrete proteases, such as MMP3, to facilitate stromal reorganisation during branching morphogenesis [85,86]. Given their involvement in orchestrating aspects of mammary gland biology, their roles in breast cancer progression have been studied extensively [87,88].

CAFs are a key component of the tumour microenvironment, influencing matrix deposition and remodelling, cancer cell growth, and immune cell recruitment [89,90]. In breast cancer, the abundance of CAFs is associated with aggressive progression and can in part be attributed to their ability to promote chemoresistance and stemness via tumour cell activation of phosphoinositide 3-kinase (PI3K)/AKT and Wnt pathways [91]. CAFs can also promote an immunosuppressive milieu, with characterisation of different CAF populations revealing a specific CAF subset, particularly enriched in TNBC, which could promote regulatory T FOXP3+ lymphocyte differentiation [92]. While the roles of CAFs in progression of established breast cancer are better understood, it remains unclear whether these same CAF functions are relevant in DCIS. Interestingly, comparison between DCIS and IDC tissue reveals that, aside from myoepithelial cell loss, a distinctive aspect of invasive progression is marked by an increase in proliferating CAFs [27].

While heterotypic co-culture of healthy luminal, myoepithelial, and fibroblast populations led to the formation of aggregated luminal-myoepithelial co-units, co-culture with fibroblasts isolated from malignant tissue disrupted their formation in an MMP- and c-MET-dependent manner [93].

Further *in vitro* co-culture studies have demonstrated the ability of fibroblasts to promote DCIS invasion, through activation of NF-κB and COX-2, driving upregulation of MMP9 and MMP14 [94]. An IL-6 paracrine mechanism has also been reported, where CAF-secreted IL-6 is able to support tumour cell invasion through the ECM [95]. Moreover, CAFs isolated from mouse models of invasive carcinoma display higher Cxcl1 levels compared with those isolated from slow growing noninvasive lesions, and are able to enhance tumour cell invasion through Cxcr2-dependent activation of NF-κB, Akt, Stat3, and mitogen-activated protein kinase (Mapk) pathways [96]. The tumour-promoting role of CAFs in mediating DCIS progression has been supported by *in vivo* studies, where co-injection of tumour cells and fibroblasts led to increased formation of invasive tumours, compared with tumour cells alone [94,97]. The prognostic relevance of tumour-promoting fibroblasts can be demonstrated in patient follow-up studies, where Notch-dependent upregulation of the fibroblast marker platelet-derived growth factor receptor beta (PDGFRβ) is associated with increased risk of recurrence in DCIS patients [98]. This is complemented by the loss of stromal Caveolin-1, a characteristic feature of breast cancer CAFs, which is also associated with progression to IDC [99].

Matrix

The ECM is a complex network of macromolecules, which modulates cell behaviour through its biochemical and biomechanical properties. Despite the established loss of the BM in the transition of DCIS to IDC, little is known about how BM assembly may be altered by cancer cells in DCIS. In the MCF10DCIS.com cell line model, increased expression of the filapodia-inducing protein, myosin-10 (MYO10), displays an anti-invasive role, with high levels correlating with prominent BM deposition [100]. Interestingly, MYO10 depletion in DCIS xenograft models results in defective BM assembly and cancer cell dispersal, highlighting a mechanism whereby alterations in inadequate BM assembly, rather than BM degradation, may underpin the progression of DCIS [100]. However, it is worth noting that while MYO10-deficient tumours displayed more cancer cell dissemination, it is unclear whether this is a direct consequence of a compromised BM, or whether it is their gain in invasive capacity that drives reduced matrix deposition [100]. Further dysregulation of the ECM, demonstrated by increased collagen deposition in the peritumoural regions, is also crucial in shaping both tumour growth and metastatic dissemination [101,102]. In breast cancer, the mammary gland becomes progressively stiffer and collagen rich, compared with healthy breast tissue, with aberrant changes to matrix remodelling attributed predominantly to CAFs. Indeed, tissue stiffness correlates with cancer grade, with the presence of thick aligned collagen fibres at the invasive front of tumours correlating with worse patient outcome [103]. In addition to changes in collagen deposition and crosslinking, orientation of collagen fibres is altered during disease progression, with fibres adjacent to the tumour margin in DCIS progressing to a perpendicular orientation in IDC [103–106], enabling the formation of tracks to facilitate migration of cancer cells into the surrounding stroma [104]. While collagen fibres perpendicular to the duct are more frequently present in DCIS exhibiting poor prognostic markers, such as comedo necrosis and HER2 positivity, changes to these orientation patterns are unable to predict recurrence [107]. Temporal profiling of the matrisome, which consists of genes encoding ECM and ECM-associated proteins, in breast cancer has revealed CAF-secreted collagen XII to be a key component in the regulation of collagen I organisation, with increased secretion associated with poor prognosis [108]. Despite evidence to suggest that collagen XII can create a more pro-invasive microenvironment through alterations to fibrillary collagen architecture and stiffness, additional investigation into collagen XII as a marker for DCIS is warranted [108].

In addition to changes in collagen I architecture, alterations in the deposition of other matrix components are also implicated in promoting early-stage breast cancer progression. For example, deposition of periductal fibronectin is increased in DCIS compared with healthy ducts and is

thought to be supportive of the pro-invasive niche [45]. In addition to CAFs [109], increased fibronectin deposition can occur across cell types, with cancer cells depositing fibronectin in a semaphorin 7A (SEMA7A)-mediated manner [110], and DCIS-associated myoepithelial cells increasing its expression upon mechanical stretching [45]. In addition to the mechanical influence of the matrix on cancer cells, the collagen-dense microenvironment can provide anchorage to infiltrating immune cells, such as tumour-associated neutrophils, which may further accelerate disease progression [111]. Alterations in the extracellular mechanical properties can be detected via mechanosensors, such as integrins, with mechanosignalling enabling cancer cells to respond and transition into an invasive phenotype [112]. Indeed, a study of MCF10A mammary spheroids revealed a positive correlation between invasion and matrix stiffness, facilitated by stabilisation of the vinculin-talin-actin complex upon increased β1 integrin activation and FAK^{Y397} phosphorylation [113]. While a progressive increase in the levels and colocalisation of β1 and FAK^{Y397} was observed across normal, DCIS, and IDC clinical samples [113], protein expression was not scored and requires further work to confirm their role as markers of recurrence after DCIS treatment.

Outstanding questions

Utilising more complex *in vitro* and *in vivo* models, how can we further improve our understanding of the microenvironmental interplay that facilitates DCIS progression?

How can we apply our understanding of the DCIS microenvironment to refine the stratification of DCIS patients into low- and high-risk groups?

How can we make the most of large retrospective cohorts to effectively progress prognostic markers into the clinic?

Concluding remarks

With the microenvironment becoming more prominently recognised as a mediator of disease progression, it is likely that tumour-extrinsic markers will also be required (Figure 2 and Table 1), in conjunction with the conventional histopathological factors, to guide treatment plans. Ultimately, further understanding of the microenvironmental drivers that underpin DCIS progression will be key in orchestrating the successful translation of putative prognostic markers into clinical biomarker studies. First, investigating mechanisms of DCIS *in vitro* will require careful selection of model systems to ensure the accurate reflection of the physiological state, with complex 3D models presenting an ideal platform for these studies [114]. Currently, models examining DCIS can be constructed either from constituent cellular parts [115], or by embedding tissue pieces inside a 3D matrix [116,117]. A key step is to build a functional duct, which can then either be manipulated to mimic DCIS, or increased in complexity with the inclusion of additional cell types/matrix components [60,115–117]. Secondly, advances in *in vivo* models will offer added biological insight compared with standard mammary fat pad models, which may not be reflective of the true microenvironment in DCIS. The mouse intraductal (MIND) model is particularly advantageous as there is a greater influence of the microenvironment on progression than that offered by traditional fat pad models [118]. Here, patient-derived DCIS epithelial cells are injected intraductally via the nipple, to allow for the formation of *in situ* lesions and subsequent invasion into the surrounding stroma, will be a valuable tool going forward [119]. Finally, the marrying of extensively interrogated preclinical data with clinical outcome data from active surveillance trials for DCIS [7,17–19] will help to form the basis for subsequent biomarker studies. This, together with additional initiatives such as the £15 million (18 million USD) PRECISION (PREvent ductal Carcinoma *In Situ* Invasive Overtreatment NOW) programme, funded by Cancer Research UK and the Dutch Cancer Society, will be key in improving the translation of promising prognostic factors into clinical practice[ii]. Ultimately, these approaches will provide further biological insights that are essential in the development of noninvasive tools to distinguish indolent DCIS from progressive DCIS, effectively tackling the issue of overtreatment (see Outstanding questions).

Declaration of interests

No interests are declared.

Resources

[i]www.cancerresearchuk.org/health-professional/cancer-statistics/statistics-by-cancer-type/breast-cancer

[ii]https://cancergrandchallenges.org/teams/precision

References

1. Collins, L.C. *et al.* (2005) Outcome of patients with ductal carcinoma in situ untreated after diagnostic biopsy: results from the Nurses' Health Study. *Cancer* 103, 1778–1884
2. Sanders, M.E. *et al.* (2005) The natural history of low-grade ductal carcinoma in situ of the breast in women treated by biopsy only revealed over 30 years of long-term follow-up. *Cancer* 103, 2481–2484
3. Independent UK Panel on Breast Cancer Screening (2012) The benefits and harms of breast cancer screening: an independent review. *Lancet* 380, 1778–1786
4. Allegra, C.J. *et al.* (2010) National Institutes of Health State-of-the-Science Conference statement: diagnosis and management of ductal carcinoma in situ September 22–24, 2009. *J. Natl. Cancer Inst.* 102, 161–169
5. Erbas, B. *et al.* (2006) The natural history of ductal carcinoma in situ of the breast: a review. *Breast Cancer Res. Treat.* 97, 135–144
6. Leeper, A.D. and Dixon, J.M. (2011) DCIS of the breast: are we over-diagnosing it? Are we over-treating it? *Maturitas* 68, 295–296
7. Angarita, F.A. *et al.* (2022) De-escalating the management of in situ and invasive breast cancer. *Cancers (Basel)* 14, 4545
8. Casasent, A.K. *et al.* (2022) Learning to distinguish progressive and non-progressive ductal carcinoma in situ. *Nat. Rev. Cancer* 22, 663–678
9. Schmitz, R. *et al.* (2022) Prediction models and decision aids for women with ductal carcinoma in situ: a systematic literature review. *Cancers (Basel)* 14, 3259
10. Thompson, A.M. *et al.* (2018) Management and 5-year outcomes in 9938 women with screen-detected ductal carcinoma in situ: the UK Sloane Project. *Eur. J. Cancer* 101, 210–219
11. Cunha, P.O. *et al.* (2010) Progression of ductal carcinoma in situ from the pathological perspective. *Breast Care (Basel)* 5, 233–239
12. Elshof, L.E. *et al.* (2016) Subsequent risk of ipsilateral and contralateral invasive breast cancer after treatment for ductal carcinoma in situ: incidence and the effect of radiotherapy in a population-based cohort of 10,090 women. *Breast Cancer Res. Treat.* 159, 553–563
13. Kerlikowske, K. *et al.* (2010) Biomarker expression and risk of subsequent tumors after initial ductal carcinoma in situ diagnosis. *J. Natl. Cancer Inst.* 102, 627–637
14. Thorat, M.A. *et al.* (2021) Prognostic and predictive value of HER2 expression in ductal carcinoma in situ: results from the UK/ANZ DCIS randomized trial. *Clin. Cancer Res.* 27, 5317–5324
15. Curigliano, G. *et al.* (2015) Risk of subsequent in situ and invasive breast cancer in human epidermal growth factor receptor 2-positive ductal carcinoma in situ. *Ann. Oncol.* 26, 682–687
16. Cobleigh, M.A. *et al.* (2021) Comparison of radiation with or without concurrent trastuzumab for HER2-positive ductal carcinoma in situ resected by lumpectomy: a phase III clinical trial. *J. Clin. Oncol.* 39, 2367–2374
17. Hwang, E.S. *et al.* (2019) The COMET (Comparison of Operative versus Monitoring and Endocrine Therapy) trial: a phase III randomised controlled clinical trial for low-risk ductal carcinoma in situ (DCIS). *BMJ Open* 9, e026797
18. Francis, A. *et al.* (2015) Addressing overtreatment of screen detected DCIS; the LORIS trial. *Eur. J. Cancer* 51, 2296–2303
19. Elshof, L.E. *et al.* (2015) Feasibility of a prospective, randomised, open-label, international multicentre, phase III, non-inferiority trial to assess the safety of active surveillance for low risk ductal carcinoma in situ - The LORD study. *Eur. J. Cancer* 51, 1497–1510
20. Castro, N.P. *et al.* (2008) Evidence that molecular changes in cells occur before morphological alterations during the progression of breast ductal carcinoma. *Breast Cancer Res.* 10, R87
21. Clark, S.E. *et al.* (2011) Molecular subtyping of DCIS: heterogeneity of breast cancer reflected in pre-invasive disease. *Br. J. Cancer* 104, 120–127
22. Carraro, D.M. *et al.* (2014) Ductal carcinoma in situ of the breast: morphological and molecular features implicated in progression. *Biosci. Rep.* 34, e00090
23. Ma, X.J. *et al.* (2009) Gene expression profiling of the tumor microenvironment during breast cancer progression. *Breast Cancer Res.* 11, R7
24. Muggerud, A.A. *et al.* (2010) Molecular diversity in ductal carcinoma in situ (DCIS) and early invasive breast cancer. *Mol. Oncol.* 4, 357–368
25. Nelson, A.C. *et al.* (2018) Breaking through to the other side: microenvironment contributions to DCIS initiation and progression. *J. Mammary Gland Biol. Neoplasia* 23, 207–221
26. Lesurf, R. *et al.* (2016) Molecular features of subtype-specific progression from ductal carcinoma in situ to invasive breast cancer. *Cell Rep.* 16, 1166–1179
27. Risom, T. *et al.* (2022) Transition to invasive breast cancer is associated with progressive changes in the structure and composition of tumor stroma. *Cell* 185, 299–310.e18
28. Adriance, M.C. *et al.* (2005) Myoepithelial cells: good fences make good neighbors. *Breast Cancer Res.* 7, 190–197
29. Gudjonsson, T. *et al.* (2005) Myoepithelial cells: their origin and function in breast morphogenesis and neoplasia. *J. Mammary Gland Biol. Neoplasia* 10, 261–272
30. Barsky, S.H. (2003) Myoepithelial mRNA expression profiling reveals a common tumor-suppressor phenotype. *Exp. Mol. Pathol.* 74, 113–122
31. Shao, Z.M. *et al.* (1998) The human myoepithelial cell exerts antiproliferative effects on breast carcinoma cells characterized by p21WAF1/CIP1 induction, G2/M arrest, and apoptosis. *Exp. Cell Res.* 241, 394–403
32. Zou, Z. *et al.* (1994) Maspin, a serpin with tumor-suppressing activity in human mammary epithelial cells. *Science* 263, 526–529
33. Runswick, S.K. *et al.* (2001) Desmosomal adhesion regulates epithelial morphogenesis and cell positioning. *Nat. Cell Biol.* 3, 823–830
34. Barsky, S.H. and Karlin, N.J. (2005) Myoepithelial cells: autocrine and paracrine suppressors of breast cancer progression. *J. Mammary Gland Biol. Neoplasia* 10, 249–260
35. Sirka, O.K. *et al.* (2018) Myoepithelial cells are a dynamic barrier to epithelial dissemination. *J. Cell Biol.* 217, 3368–3381
36. Cowell, C.F. *et al.* (2013) Progression from ductal carcinoma in situ to invasive breast cancer: revisited. *Mol. Oncol.* 7, 859–869
37. Polyak, K. and Hu, M. (2005) Do myoepithelial cells hold the key for breast tumor progression? *J. Mammary Gland Biol. Neoplasia* 10, 231–247
38. Russell, T.D. *et al.* (2015) Myoepithelial cell differentiation markers in ductal carcinoma in situ progression. *Am. J. Pathol.* 185, 3076–3089
39. Allinen, M. *et al.* (2004) Molecular characterization of the tumor microenvironment in breast cancer. *Cancer Cell* 6, 17–32
40. Toss, M.S. *et al.* (2020) The prognostic significance of immune microenvironment in breast ductal carcinoma in situ. *Br. J. Cancer* 122, 1496–1506
41. Toss, M.S. *et al.* (2018) Prognostic significance of tumor-infiltrating lymphocytes in ductal carcinoma in situ of the breast. *Mod. Pathol.* 31, 1226–1236
42. Pruneri, G. *et al.* (2017) The prevalence and clinical relevance of tumor-infiltrating lymphocytes (TILs) in ductal carcinoma in situ of the breast. *Ann. Oncol.* 28, 321–328
43. Hendry, S. *et al.* (2017) Relationship of the breast ductal carcinoma in situ immune microenvironment with clinicopathological and genetic features. *Clin. Cancer Res.* 23, 5210–5217
44. Gudjonsson, T. *et al.* (2002) Normal and tumor-derived myoepithelial cells differ in their ability to interact with luminal breast epithelial cells for polarity and basement membrane deposition. *J. Cell Sci.* 115, 39–50
45. Hayward, M.-K. *et al.* (2022) Mechanostimulation of breast myoepithelial cells induces functional changes associated with DCIS progression to invasion. npj. *Breast Cancer* 8, 109
46. Allen, M.D. *et al.* (2014) Altered microenvironment promotes progression of preinvasive breast cancer: myoepithelial expression of alphavbeta6 integrin in DCIS identifies high-risk patients and predicts recurrence. *Clin. Cancer Res.* 20, 344–357
47. Sarper, M. *et al.* (2017) Loss of MMP-8 in ductal carcinoma in situ (DCIS)-associated myoepithelial cells contributes to tumour promotion through altered adhesive and proteolytic function. *Breast Cancer Res.* 19, 33
48. Lo, P.K. *et al.* (2017) Tumor-associated myoepithelial cells promote the invasive progression of ductal carcinoma in situ

through activation of TGFβ signaling. *J. Biol. Chem.* 292, 11466–11484
49. Allen, M.D. *et al.* (2014) αvβ6 Expression in myoepithelial cells: a novel marker for predicting DCIS progression with therapeutic potential. *Cancer Res.* 74, 5942–5947
50. Brown, K.A. (2021) Metabolic pathways in obesity-related breast cancer. *Nat. Rev. Endocrinol.* 17, 350–363
51. Devericks, E.N. *et al.* (2022) The obesity-breast cancer link: a multidisciplinary perspective. *Cancer Metastasis Rev.* 41, 607–625
52. Kim, H.S. *et al.* (2018) IL-6-mediated cross-talk between human preadipocytes and ductal carcinoma in situ in breast cancer progression. *J. Exp. Clin. Cancer Res.* 37, 200
53. Andarawewa, K.L. *et al.* (2005) Stromelysin-3 is a potent negative regulator of adipogenesis participating to cancer cell-adipocyte interaction/crosstalk at the tumor invasive front. *Cancer Res.* 65, 10862–10871
54. Delort, L. *et al.* (2021) The adipose microenvironment dysregulates the mammary myoepithelial cells and could participate to the progression of breast cancer. *Front. Cell Dev. Biol.* 8, 571948
55. Picon-Ruiz, M. *et al.* (2016) Interactions between adipocytes and breast cancer cells stimulate cytokine production and drive Src/Sox2/miR-302b–mediated malignant progression. *Cancer Res.* 76, 491–504
56. Gernapudi, R. *et al.* (2015) Targeting exosomes from preadipocytes inhibits preadipocyte to cancer stem cell signaling in early-stage breast cancer. *Breast Cancer Res. Treat.* 150, 685–695
57. Chamberlin, T. *et al.* (2017) Obesity reversibly depletes the basal cell population and enhances mammary epithelial cell estrogen receptor alpha expression and progenitor activity. *Breast Cancer Res.* 19, 128
58. Iyengar, N.M. *et al.* (2016) Obesity and cancer mechanisms: tumor microenvironment and inflammation. *J. Clin. Oncol.* 34, 4270–4276
59. Carter, J.M. *et al.* (2018) Macrophagic "crown-like structures" are associated with an increased risk of breast cancer in benign breast disease. *Cancer Prev. Res.* 11, 113–119
60. Wilcz-Villega, E. *et al.* (2020) Macrophages induce malignant traits in mammary epithelium via IKKε/TBK1 kinases and the serine biosynthesis pathway. *EMBO Mol. Med.* 12, e10491
61. Iyengar, N.M. *et al.* (2016) Systemic correlates of white adipose tissue inflammation in early-stage breast cancer. *Clin. Cancer Res.* 22, 2283–2289
62. Maliniak, M.L. *et al.* (2020) Detection of crown-like structures in breast adipose tissue and clinical outcomes among African-American and White women with breast cancer. *Breast Cancer Res.* 22, 65
63. Almekinders, M.M.M. *et al.* (2021) Breast adipocyte size associates with ipsilateral invasive breast cancer risk after ductal carcinoma in situ. *npj Breast Cancer* 7, 31
64. Visser, L.L. *et al.* (2018) Clinicopathological risk factors for an invasive breast cancer recurrence after ductal carcinoma in situ—a nested case–control study. *Clin. Cancer Res.* 24, 3593–3601
65. Hanahan, D. and Weinberg, R.A. (2011) Hallmarks of cancer: the next generation. *Cell* 144, 646–674
66. Gil Del Alcazar, C.R. *et al.* (2020) Immune escape during breast tumor progression. *Cancer Immunol. Res.* 8, 422–427
67. Allen, M.D. and Jones, L.J. (2015) The role of inflammation in progression of breast cancer: Friend or foe? (Review). *Int. J. Oncol.* 47, 797–805
68. Ibrahim, E.M. *et al.* (2014) The prognostic value of tumor-infiltrating lymphocytes in triple-negative breast cancer: a meta-analysis. *Breast Cancer Res. Treat.* 148, 467–476
69. Adams, S. *et al.* (2014) Prognostic value of tumor-infiltrating lymphocytes in triple-negative breast cancers from two phase III randomized adjuvant breast cancer trials: ECOG 2197 and ECOG 1199. *J. Clin. Oncol.* 32, 2959–2966
70. Kim, M. *et al.* (2020) Immune microenvironment in ductal carcinoma in situ: a comparison with invasive carcinoma of the breast. *Breast Cancer Res.* 22, 32
71. Gil Del Alcazar, C.R. *et al.* (2017) Immune escape in breast cancer during in situ to invasive carcinoma transition. *Cancer Discov.* 7, 1098–1115
72. Chen, X.-Y. *et al.* (2020) Higher density of stromal M2 macrophages in breast ductal carcinoma in situ predicts recurrence. *Virchows Arch.* 476, 825–833
73. Linde, N. *et al.* (2018) Macrophages orchestrate breast cancer early dissemination and metastasis. *Nat. Commun.* 9, 21
74. Campbell, M.J. *et al.* (2017) Characterizing the immune microenvironment in high-risk ductal carcinoma in situ of the breast. *Breast Cancer Res. Treat.* 161, 17–28
75. Guidi, A.J. *et al.* (1994) Microvessel density and distribution in ductal carcinoma in situ of the breast. *JNCI: J. Natl. Cancer Inst.* 86, 614–619
76. Zhang, Z. *et al.* (2016) Prognostic significance of high VEGF-C expression for patients with breast cancer: an update meta analysis. *PLoS One* 11, e0165725
77. Engels, K. *et al.* (1997) Distinct angiogenic patterns are associated with high-grade in situ ductal carcinomas of the breast. *J. Pathol.* 181, 207–212
78. Lee, A.H. *et al.* (1997) Angiogenesis and inflammation in ductal carcinoma in situ of the breast. *J. Pathol.* 181, 200–206
79. Teo, N.B. *et al.* (2003) Angiogenesis and invasive recurrence in ductal carcinoma in situ of the breast. *Eur. J. Cancer* 39, 38–44
80. Wülfing, P. *et al.* (2005) Expression patterns of angiogenic and lymphangiogenic factors in ductal breast carcinoma in situ. *Br. J. Cancer* 92, 1720–1728
81. Lee, A.H. *et al.* (1999) Angiogenesis and expression of thymidine phosphorylase by inflammatory and carcinoma cells in ductal carcinoma in situ of the breast. *J. Pathol.* 187, 285–290
82. Nguyen, M. *et al.* (2000) The human myoepithelial cell displays a multifaceted anti-angiogenic phenotype. *Oncogene* 19, 3449–3459
83. Nguyen-Ngoc, K.-V. *et al.* (2012) ECM microenvironment regulates collective migration and local dissemination in normal and malignant mammary epithelium. *Proc. Natl. Acad. Sci.* 109, E2595–E2604
84. Hildenbrand, R. and Arens, N. (2004) Protein and mRNA expression of uPAR and PAI-1 in myoepithelial cells of early breast cancer lesions and normal breast tissue. *Br. J. Cancer* 91, 564–571
85. Inman, J.L. *et al.* (2015) Mammary gland development: cell fate specification, stem cells and the microenvironment. *Development* 142, 1028–1042
86. Wiseman, B.S. *et al.* (2003) Site-specific inductive and inhibitory activities of MMP-2 and MMP-3 orchestrate mammary gland branching morphogenesis. *J. Cell Biol.* 162, 1123–1133
87. Houthuijzen, J.M. and Jonkers, J. (2018) Cancer-associated fibroblasts as key regulators of the breast cancer tumor microenvironment. *Cancer Metastasis Rev.* 37, 577–597
88. Feinberg, T.Y. *et al.* (2018) Divergent matrix-remodeling strategies distinguish developmental from neoplastic mammary epithelial cell invasion programs. *Dev. Cell* 47, 145–160.e6
89. Sahai, E. *et al.* (2020) A framework for advancing our understanding of cancer-associated fibroblasts. *Nat. Rev. Cancer* 20, 174–186
90. Kalluri, R. (2016) The biology and function of fibroblasts in cancer. *Nat. Rev. Cancer* 16, 582–598
91. Xiang, L. *et al.* (2020) Taxotere-induced WNT16 expression in carcinoma-associated fibroblasts might associate with progression and chemoresistance of breast cancer. *Ann. Clin. Lab. Sci.* 50, 205–212
92. Costa, A. *et al.* (2018) Fibroblast heterogeneity and immunosuppressive environment in human breast cancer. *Cancer Cell* 33, 463–479.e10
93. Holliday, D.L. *et al.* (2009) Novel multicellular organotypic models of normal and malignant breast: tools for dissecting the role of the microenvironment in breast cancer progression. *Breast Cancer Res.* 11, R3
94. Hu, M. *et al.* (2009) Role of COX-2 in epithelial-stromal cell interactions and progression of ductal carcinoma in situ of the breast. *Proc. Natl. Acad. Sci. U. S. A.* 106, 3372–3377
95. Osuala, K.O. *et al.* (2015) Il-6 signaling between ductal carcinoma in situ cells and carcinoma-associated fibroblasts mediates tumor cell growth and migration. *BMC Cancer* 15, 584
96. Bernard, S. *et al.* (2018) CXCL1 derived from mammary fibroblasts promotes progression of mammary lesions to invasive

carcinoma through CXCR2 dependent mechanisms. *J. Mammary Gland Biol. Neoplasia* 23, 249–267
97. Brummer, G. *et al.* (2018) Chemokine signaling facilitates early-stage breast cancer survival and invasion through fibroblast-dependent mechanisms. *Mol. Cancer Res.* 16, 296–308
98. Strell, C. *et al.* (2019) Impact of epithelial-stromal interactions on peritumoral fibroblasts in ductal carcinoma in situ. *J. Natl. Cancer Inst.* 111, 983–995
99. Witkiewicz, A.K. *et al.* (2009) Stromal caveolin-1 levels predict early DCIS progression to invasive breast cancer. *Cancer Biol. Ther.* 8, 1071–1079
100. Peuhu, E. *et al.* (2022) MYO10-filopodia support basement membranes at pre-invasive tumor boundaries. *Dev. Cell* 57, 2350–2364.e7
101. Winkler, J. *et al.* (2020) Concepts of extracellular matrix remodelling in tumour progression and metastasis. *Nat. Commun.* 11, 5120
102. Kaushik, S. *et al.* (2016) From transformation to metastasis: deconstructing the extracellular matrix in breast cancer. *Cancer Metastasis Rev.* 35, 655–667
103. Acerbi, I. *et al.* (2015) Human breast cancer invasion and aggression correlates with ECM stiffening and immune cell infiltration. *Integr. Biol. (Camb.)* 7, 1120–1134
104. Conklin, M.W. *et al.* (2011) Aligned collagen is a prognostic signature for survival in human breast carcinoma. *Am. J. Pathol.* 178, 1221–1232
105. Provenzano, P.P. *et al.* (2006) Collagen reorganization at the tumor-stromal interface facilitates local invasion. *BMC Med.* 4, 38
106. Koorman, T. *et al.* (2022) Spatial collagen stiffening promotes collective breast cancer cell invasion by reinforcing extracellular matrix alignment. *Oncogene* 41, 2458–2469
107. Conklin, M.W. *et al.* (2018) Collagen alignment as a predictor of recurrence after ductal carcinoma in situ. *Cancer Epidemiol. Biomark. Prev.* 27, 138–145
108. Papanicolaou, M. *et al.* (2022) Temporal profiling of the breast tumour microenvironment reveals collagen XII as a driver of metastasis. *Nat. Commun.* 13, 4587
109. Attieh, Y. *et al.* (2017) Cancer-associated fibroblasts lead tumor invasion through integrin-β3-dependent fibronectin assembly. *J. Cell Biol.* 216, 3509–3520
110. Tarullo, S.E. *et al.* (2020) Postpartum breast cancer progression is driven by semaphorin 7a-mediated invasion and survival. *Oncogene* 39, 2772–2785
111. García-Mendoza, M.G. *et al.* (2016) Neutrophils drive accelerated tumor progression in the collagen-dense mammary tumor microenvironment. *Breast Cancer Res.* 18, 49
112. Schedin, P. and Keely, P.J. (2011) Mammary gland ECM remodeling, stiffness, and mechanosignaling in normal development and tumor progression. *Cold Spring Harb. Perspect. Biol.* 3, a003228
113. Rubashkin, M.G. *et al.* (2014) Force engages vinculin and promotes tumor progression by enhancing PI3K activation of phosphatidylinositol (3, 4, 5)-triphosphate. *Cancer Res.* 74, 4597–4611
114. Carter, E.P. *et al.* (2021) Tumour microenvironment 3D-modelling: simplicity to complexity and back again. *Trends Cancer* 7, 1033–1046
115. Carter, E.P. *et al.* (2017) A 3D in vitro model of the human breast duct: a method to unravel myoepithelial-luminal interactions in the progression of breast cancer. *Breast Cancer Res.* 19, 1–10
116. Sokol, E.S. *et al.* (2017) SMARCE1 is required for the invasive progression of in situ cancers. *Proc. Natl. Acad. Sci. U. S. A.* 114, 4153–4158
117. Sokol, E.S. *et al.* (2016) Growth of human breast tissues from patient cells in 3D hydrogel scaffolds. *Breast Cancer Res.* 18, 19
118. Sflomos, G. *et al.* (2016) A preclinical model for ERα-positive breast cancer points to the epithelial microenvironment as determinant of luminal phenotype and hormone response. *Cancer Cell* 29, 407–422
119. Hong, Y. *et al.* (2022) Mouse-INtraDuctal (MIND): an in vivo model for studying the underlying mechanisms of DCIS malignancy. *J. Pathol.* 256, 186–201